

ORIGINAL ARTICLE

Surgical tips for type II thyroplasty for adductor spasmodic dysphonia: modified technique after reviewing unsatisfactory cases

NOBUHIKO ISSHIKI¹ & TETSUJI SANUKI²

¹Kyoto Voice Surgery Center, Kyoto and ²Department of Otolaryngology-Head & Neck Surgery, Graduate School of Medicine, Kumamoto University, Kumamoto, Japan

Abstract

Conclusion: Use of the titanium bridge, both at the top and bottom corners of the incised thyroid cartilage, is essential for success. Most importantly, these procedures should be done with minimal damage to the tissues involved, using fine instruments. **Objectives:** Type II thyroplasty that aims at lateralization of the vocal folds for spasmodic dysphonia is a type of surgery that requires utmost surgical caution, because of the extremely delicate site for surgical intervention, critically sensitive adjustment, and difficult procedures to maintain the incised cartilages in a correct position. **Patients and methods:** By means of a postoperative questionnaire and examinations, analyses were made of the relation in each case between the detailed surgical records and the outcomes in terms of subjective complaints, vocal features, and laryngeal as well as aerodynamic findings. **Results:** It was found that surgical failures or unsatisfactory results arise most frequently from certain clear mechanical faults. The critical procedures that most affected the results included: (1) incision and separation of the thyroid cartilage at the midline; (2) adjustment of separation width for optimal voice; (3) cartilage-perichondrium separation for holding an appropriate titanium bridge; and (4) installation and fixation of titanium bridges.

Keywords: Spasmodic dysphonia, thyroplasty, surgical technique, treatment, voice

Introduction

Since we first reported success with the midline type II thyroplasty (lateralization) for treatment of adductor spasmodic dysphonia (AdSD) [1] 8 years ago, and because of the success rate, a number of patients have been referred from other areas of Japan to our Kyoto Voice Surgery Center. This surgery is based on the hypothesis that the voice distortion in AdSD is a consequence of excessively tight closure of the glottis on phonation, regardless of the etiology or lesion site. Most of the previous effective treatments have in fact aimed at relieving this tight closure, including recurrent nerve section [2,3] or avulsion [4], extirpation of the adductor muscle [5–7], electrical stimulation of the recurrent laryngeal nerve [8], and currently the most popular treatment – botulinum toxin injection [9–11].

Type II thyroplasty differs from previous treatments in that this surgery does not involve any surgical intervention into the laryngeal muscle, nerve or vocal

folds. Type II thyroplasty for AdSD follows the thinking that intervention in the thyroid cartilage is unrelated to the underlying lesion. This appears contrary to the common logic of surgery, in which a disease is usually approached directly, and may be likened to conducting an operation without knowing what to remove or where the lesion is located. Therefore, this surgical procedure has been regarded with some suspicion. Type II thyroplasty is intended to prevent the spasmodic tight glottal closure at the terminal stage of phonation, which is a purely mechanical process [12,13], leaving untouched the lesion or structures directly involved. No interventions have ever been made in the vocal folds. The vocal fold structure is never violated, so surgical failure, if any, is hypothesized to be a continuing problem at the mechanical level.

An attempt was made to identify any possible pitfalls in this surgery by thoroughly reviewing the postoperative results as well as intraoperative

Correspondence: Nobuhiko Isshiki MD, 22 Minami-yonnotsubo-cho Iwakura, Sakyo-ku, Kyoto, 606-0033, Japan. Tel: +81 75 721 3080. Fax: +81 75 721 7267. E-mail: nobyishiki@yahoo.co.jp

(Received 21 January 2009; accepted 2 April 2009)

ISSN 0001-6489 print/ISSN 1651-2251 online © 2010 Informa UK Ltd. (Informa Healthcare, Taylor & Francis AS)

DOI: 10.3109/00016480903036255

findings in each revision procedure or unsatisfactory case.

Patients and methods

As of the end of December 2005, 95 type II thyroplasties had been performed in 90 patients. Of these, the most recent 41 patients (December 2002 to December 2005) all received a titanium bridge for thyroid cartilage stabilization after vocal fold lateralization, and a minimum 6 months postoperative follow-up data were obtained through questionnaire and clinical examinations. The results were analyzed in terms of subjective satisfaction, voice quality, and laryngoscopic and aerodynamic findings. These findings were reported in the first part of this study (part 1) [14].

Those patients with an extremely short follow-up period (33 patients) and those who could not be followed up were excluded from analysis. Failure cases underwent a particularly thorough examination in an attempt to uncover the factors responsible for failure [14,15]. In the results of part 1, approximately 69% of patients expressed complete satisfaction, indicating that their normal voice had been restored. Another 22% reported much improvement but occasionally had some complaints, and 9% were in some way unsatisfied with the procedure [14].

We also compared the outcomes of the 41 patients who received thyroid cartilage stabilization with titanium bridges to those of 17 earlier patients in whom a silicone wedge was used, despite the incomplete nature of the records and documents available for these patients. With this knowledge, modifications of the surgical procedures have been made step by step on the basis of immediate postoperative analysis after each case.

Herein we summarize the recent modifications progressively made in our surgical technique for surgical treatment of AdSD.

Results

Modified technique for type II thyroplasty

Review of the surgical results in our patients helped to bring about two major modifications in the surgical technique for type II thyroplasty, as described below.

First, a specially devised titanium bridge [16] (Figure 1) (Patent: US7090697) is now used in place of a silicone wedge for fixation of the incised thyroid cartilage in the newly abducted position.

Second, two titanium bridges are now used for firm and permanent fixation of the thyroid cartilage at both the upper and lower corners (see Figure 7). These

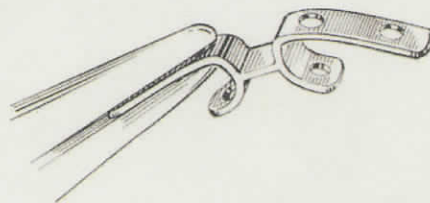


Figure 1. Titanium bridge.

implants allow better stabilization of the thyroid cartilage and more precise correction of the excessive adduction forces in spasmodic dysphonia. However, the success of any surgery depends on attention to detail, and type II thyroplasty is no exception. To this end we present the main surgical steps in performing this operation and details learned from our review of the surgical results in this group of patients.

Salient points in surgical technique of type II thyroplasty

Thyroplasty skin incision. Under local anesthesia, a horizontal neck skin incision, about 3 cm in length, is made at a level a little lower than the midpoint (anterior commissure) of the thyroid cartilage.

Exposure of thyroid cartilage. A median vertical strip of the thyroid cartilage is exposed from well above the notch down to the cricothyroid membrane (Figure 2)

Sectioning of the thyroid cartilage precisely at the median line (Figure 2). After the median line of the thyroid cartilage is marked precisely, the cartilage is sectioned carefully to prevent cutting the inner perichondrium and the mucous membrane. First a BP 11 knife is used, subsequently supplemented by a tiny

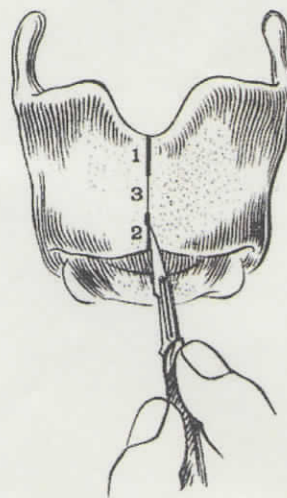


Figure 2. Incision of the thyroid cartilage at the median line.

triangular knife such as is used for circular incision of the external meatus during tympanoplasty, along with other fine separators. A fine-tipped fissure burr or a fine chisel may be used for cutting calcified cartilage. Extreme caution is needed during this part of the procedure. Fine instruments are used for separation or undermining of the thyroid cartilage internally (Figure 3b and Figure 4). The midline cartilage incision is best performed in stages to minimize potential injury to the internal larynx. The order of the median cartilage incision is illustrated in Figure 2. First, the upper one-third is incised, since this is a safe region with an abundance of tissue behind the cartilage (Figure 5). Second, the lower one-third is cut where the soft tissue layer is thin. An inadvertent perforation into the airway here, although less likely to occur, would not deteriorate the voice as much as at the anterior commissure. Finally, the middle one-third, or the anterior commissure region, is incised. This spot is the most sensitive area, with a very thin perichondro-mucous membrane behind the cartilage. The membrane just above the anterior commissure is the thinnest and therefore quite vulnerable to the forces of stretching during cartilage separation and lateralization.

A crude instrument such as an oscillating saw should not be used to make the thyrotomy incision. Once the thyroid cartilage incision is complete the incised cartilage edges are retracted to search for an optimal separation.

Careful subperichondrial elevation and separation between the thyroid cartilage and the inner perichondrium. Before the undermining with a fine, sharp elevator (Figure 3b and 4), a shallow incision along the lower margin of the thyroid cartilage is made, as indicated by an arrow in Figure 5, toward the lower border of the thyroid cartilage to cut through the tendinous ligamentous portion connecting the cartilage with the cricothyroid membrane (Figure 3a). Starting from the incision, separation is made (Figure 3b) just along the back side

of the cartilage, so as not to break through the perichondrium. Cartilage-perichondrial separation is also performed laterally from the median incision (Figure 4) within the area to hold the titanium bridge. Similarly, the upper portion of the thyroid cartilage incision is also undermined to hold the bridge. Undermining is not done widely around the anterior commissure, to prevent the lowering of the vocal pitch. The bridge is not placed over the anterior commissure (see Figure 7).

Optimal thyroid cartilage separation. We are now ready for a decision as to the optimal width of separation of the incised cartilage edges, based on the patient's ease of phonation and voice quality intraoperatively. The incised cartilage edges are gradually separated with the use of curved-tip hemostatic forceps (Figure 6a), or a special separator (Figure 6b), being careful not to injure the perichondrium with the tip of the instrument. While asking the patient to produce vocal sounds, such as the vowel /a/, as well as other words or phrases, the separation width is adjusted to the optimal point where the voice can be produced easily without any strangulation sensation experienced by the patient. Too wide a separation would make the voice breathy and weak. At the moment when the glottis on phonation is adequately widened, the patient always realizes the difference in the ease of voice production, saying 'it is much easier now.' The adequate width of separation ranges from 2 to 6 mm, most frequently 3–4 mm. A set of bridges of various widths should be ready for use.

Titanium bridges fixation. After confirming the space created under the thyroid cartilage to hold the bridge, a selected bridge is bent with pliers to comply with the curvature of the thyroid cartilage, and is gently set holding the cartilage, one side after the other, with the help of an assistant surgeon. The edges of the incised cartilage should never be damaged, as this would cause narrowing of the intended width of separation,

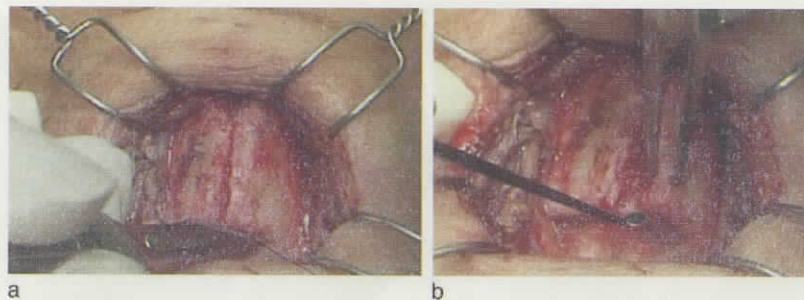


Figure 3. Shallow incision of the connective tissue down to the lower border of cartilage (a), from where separation between the cartilage and the inner perichondrium starts (b).

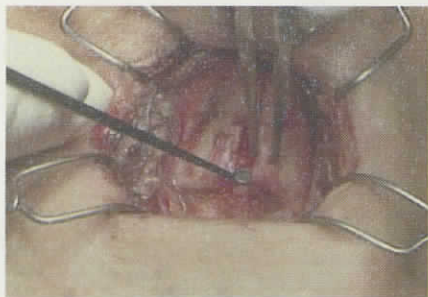


Figure 4. Separation procedure is conducted from the median incision line as well, using a fine instrument.

reducing the effect of surgery. The bridge is fixed to the cartilage with four sutures of 4-0 nylon, either passing through the hole of the bridge, or holding the implant with a suture surrounding the bridge completely (Figure 7).

Management of mucosal perforation. If a perforation of the airway occurs during surgery (usually just above the anterior commissure), then the mucosal tear should be reinforced with a muscle flap. Mucosal dehiscence in this thin and vulnerable soft tissue is not uncommon, but attempting to close the perforation with mucosal sutures will only make the hole larger.

Instead, the salient point in covering any perforation inadvertently created in the median line is that the lower end of the sternohyoid muscle flap is

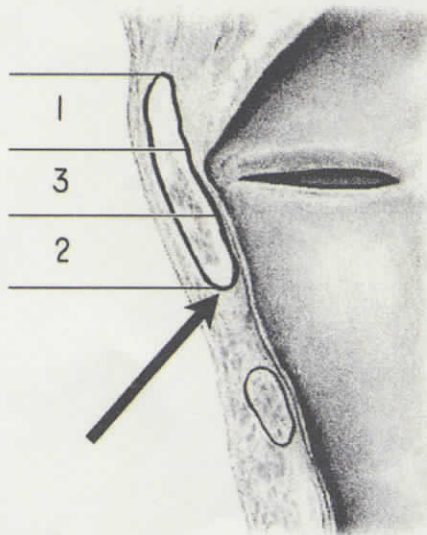


Figure 5. Soft tissue behind the cartilage: the upper third, labeled 1, has an abundant soft tissue behind the cartilage, while the middle portion, labeled 2, has a thin but strong tissue connecting the vocal folds (anterior commissure) to the cartilage. The perichondrium-mucosa soft tissue behind the cartilage is thinnest just above the anterior commissure.

sutured to the cartilage at the sides of the perforation, instead of the thin and vulnerable soft tissues around the perforation. This seals the area nicely and aids in the healing process.

Discussion

There are several advantages in using the type II thyroplasty technique for treating AdSD. First, the effect is stable and any vocal improvement is sustained without recurrence of the dystonia, in contrast to the requirement for repeated injection of botulinum toxin. Second, intraoperative adjustment is possible, so as to allow the patient to aid us in eliminating the subjective difficulty they have during phonation (effort of speech) and helping to acquire what that patient feels to be the optimal voice. Third, no direct surgical intervention into the vocal folds is required, obviating the risk of inevitable scarring and possible deterioration of the voice. Fourth, there is no iatrogenic disability created such as vocal fold paralysis, or deprivation of adductor muscle function, temporarily or permanently. Finally, the procedure is reversible and re-adjustable.

Despite the above advantages, the technique does not seem to have gained widespread acceptance as a treatment for AdSD. There seem to be two main reasons why this type of surgery has not been well accepted as the treatment of choice for AdSD: one theoretical and the other technical.

Theoretically speaking, type II thyroplasty for AdSD changes only the thyroid cartilage, which is unrelated to the lesion site. To understand why this approach might work, however, it is essential to understand that the mechanism for phonation consists of two distinctly separate phases: the physiological and the mechanical (Figure 8). Until the moment when the vocal folds are adducted to the midline to close the glottis, and the expiratory airflow comes up to the glottis, the entire phonation process is in the physiological phase. This is quickly followed by the mechanical phase where the laws of physics solely apply. Thyroplasty is a surgical procedure affecting only the mechanical phase, while the physiological phase is affected only indirectly.

As the concept of thyroplasties for treating vocal fold paralysis has been well accepted, one must wonder why it is not accepted as a treatment for AdSD. One reason may be derived from whether the findings are visual or not. Excessively tight glottal closures are not easy to identify, while imperfect glottis closure in cases of vocal fold paralysis is quite easy to recognize.

From the technical perspective, lateralization of the vocal folds at the critically sensitive region around

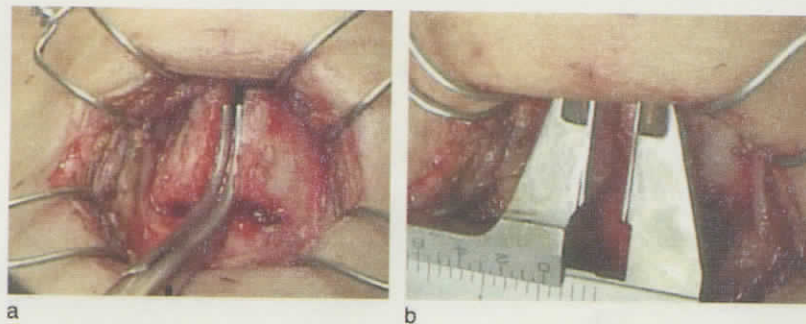


Figure 6. Spreading the incised edges, using Pean's hemostatic forceps with a specially curved tip (a) or a special instrument (Nonius caliper type) (b).

the anterior commissure requires a high level of surgical skill. It is a precise surgery that may be likened to cutting through a thick cardboard, without cutting the tape pasted on the back of the board material. Therefore, there are few surgeons sufficiently specialized to engage exclusively in this type of surgery, and the outcomes of type II thyroplasty appear to be directly dependent on the surgical technique used [17–19]. The latter authors reported rather poor results for the surgery. After a 12-month follow-up period only 22.2% and 33.3% of patients had moderate to good improvement in symptom severity and vocal effort, respectively [19]. However, their reports did not discuss any possible causes for the failure. Inadequate technique resulting in consequent poor outcomes would only delay the acceptance of this procedure. The success of surgery entirely depends on whether or not the incised cartilage edges are held apart at the precise spot for best vocal output with no excessive effort of speech, and whether or not they remain adequately separated over time. An appropriate device for maintaining the separation – such as a titanium bridge – is essential.

Although type II thyroplasty seems to be on the verge of becoming established as the preferred surgical method for treating AdSD, there are many issues that remain to be studied. Even though the symptom of stress-strangled vocalization had mostly

disappeared postoperatively, the effect of mechanical changes on the neurophysiological process for phonation as to whether there is any subsidence in the spasmodic impulses or not remains uncertain. We know from past experience that patients with AdSD treated with unilateral RLN sectioning will regain their spasmodic voice if the vocal folds end up too close together or if they are brought together to try to correct an overly breathy voice. Thus it appears that if the brain of the AdSD patient has a chance to generate a spasmodic voice, it will. On the other hand, we observed that the postoperative findings in patients with AdSD based in tremor tended to dwindle rather gradually and belatedly after thyroplasty, suggesting that some subglottal pressure reflex may be involved in generating initial voice tremor. It may be that the tremor is caused by neural impulses, while the stragulation can mostly be relieved mechanically.

Finally, electromyographic investigation of the adductor muscles during an asymptomatic period after operation would be of great interest, hopefully providing a clue to the etiology and mechanism of spasmodic dysphonia.

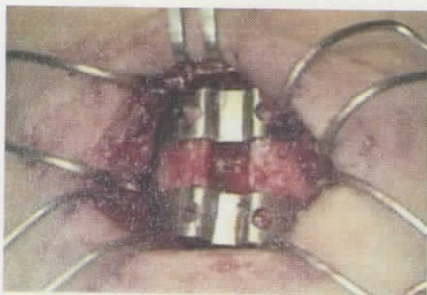


Figure 7. The titanium bridges are installed and fixed by 4-0 nylon sutures.

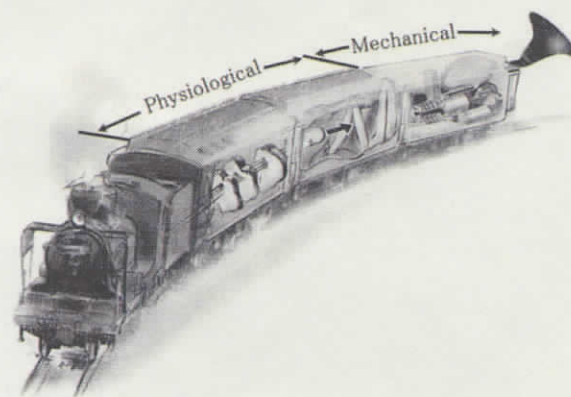


Figure 8. The mechanism for phonation consists of two separate phases in series. It may be likened to a train: physiological trains connected with the mechanical one at the end.

Conclusions

Type II thyroplasty aims at slight lateralization of the vocal folds by expansion of the thyroid cartilage anteriorly. Success of the surgery entirely depends on whether or not the thyroid cartilage that is incised at the midline is laterally expanded to an adequate width and fixed permanently using titanium bridges.

Since the site of surgery is very delicate and somewhat fragile, several elaborate surgical techniques, some of which are described here, are essential for achieving a successful outcome. Installing the titanium bridges at both the upper and lower corners of the incised thyroid cartilage edges by using the fine instruments is of critical importance for the overall success of this operation.

Declaration of interest: The authors report no conflicts of interest. The authors alone are responsible for the content and writing of the paper.

References

- [1] Isshiki N, Tsuji DH, Yamamoto Y, Iizuka Y. Midline lateralization thyroplasty for adductor spasmodic dysphonia. *Ann Otol Rhinol Laryngol* 2000;109:187-93.
- [2] Dedo HH. Recurrent laryngeal nerve section for spastic dysphonia. *Ann Otol Rhinol Laryngol* 1976;85:451-9.
- [3] Carpenter RJ 3rd, Henley-Cohn JL, Snyder GG 3rd. Spastic dysphonia: treatment by selective section of the recurrent laryngeal nerve. *Laryngoscope* 1979;89:2000-3.
- [4] Weed DT, Jewett BS, Rainey C, Zeale DL, Stone RE, Ossoff RH, et al. Long-term follow-up of recurrent laryngeal nerve avulsion for the treatment of spastic dysphonia. *Ann Otol Rhinol Laryngol* 1996;105:592-601.
- [5] Genack SH, Woo P, Colton RH, Goyette D. Partial thyroarytenoid myectomy: an animal study investigating a proposed new treatment for adductor spasmodic dysphonia. *Otolaryngol Head Neck Surg* 1993;108:256-64.
- [6] Woo P. Carbon dioxide laser-assisted thyroarytenoid myectomy. *Lasers Surg Med* 1990;10:438-43.
- [7] Nakamura K, Muta H, Watanabe Y, Mochizuki R, Yoshida T, Suzuki M. Surgical treatment for adductor spasmodic dysphonia - efficacy of bilateral thyroarytenoid myectomy under microlaryngoscopy. *Acta Otolaryngol* 2008;128:1348-53.
- [8] Friedman M, Toriumi DM, Grybauskas VT, Applebaum EL. Implantation of a recurrent laryngeal nerve stimulator for the treatment of spastic dysphonia. *Ann Otol Rhinol Laryngol* 1989;98:130-4.
- [9] Blitzer A, Brin MF, Fahn S, Lovelace RE. Localized injections of botulinum toxin for the treatment of focal laryngeal dystonia (spastic dysphonia). *Laryngoscope* 1988;98:193-7.
- [10] Ludlow CL, Naunton RF, Sedory SE, Schulz GM, Hallett M. Effects of botulinum toxin injections on speech in adductor spasmodic dysphonia. *Neurology* 1988;38:1220-5.
- [11] Zwirner P, Murry T, Swenson M, Woodson GE. Effects of botulinum toxin therapy in patients with adductor spasmodic dysphonia: acoustic, aerodynamic, and videoendoscopic findings. *Laryngoscope* 1992;102:400-6.
- [12] Isshiki N. Vocal mechanics as the basis for phonosurgery. *Laryngoscope* 1998;108:1761-6.
- [13] Isshiki N. Progress in laryngeal framework surgery. *Acta Otolaryngol* 2000;120:120-7.
- [14] Sanuki T, Isshiki N. Overall evaluation of effectiveness of type II thyroplasty for adductor spasmodic dysphonia. *Laryngoscope* 2007;117:2255-9.
- [15] Sanuki T, Isshiki N. Outcomes of type II thyroplasty for adductor spasmodic dysphonia: analysis of revision and unsatisfactory cases. *Acta Otolaryngol* 2009 (in press).
- [16] Isshiki N, Yamamoto I, Fukagai S. Type 2 thyroplasty for spasmodic dysphonia: fixation using a titanium bridge. *Acta Otolaryngol* 2004;124:309-12.
- [17] Isshiki N, Haji T, Yamamoto Y, Mahieu HF. Thyroplasty for adductor spasmodic dysphonia: further experiences. *Laryngoscope* 2001;111:615-21.
- [18] Tucker HM. Laryngeal framework surgery in the management of spasmodic dysphonia. Preliminary report. *Ann Otol Rhinol Laryngol* 1989;98:52-4.
- [19] Chan SW, Baxter M, Oates J, Yorston A. Long-term results of type II thyroplasty for adductor spasmodic dysphonia. *Laryngoscope* 2004;114:1604-8.